

# Varicocele, hypoxia and male infertility. Fluid Mechanics analysis of the impaired testicular venous drainage system

Yigal Gat<sup>1,4</sup>, Zvi Zukerman<sup>1</sup>, Joana Chakraborty<sup>3</sup> and Michael Gornish<sup>2</sup>

<sup>1</sup>Andrology Unit, Department of Obstetrics and Gynecology, and <sup>2</sup>Department of Radiology and the Interventional and Vascular Unit, Rabin Medical Center, Beilinson Campus, Petah Tiqva and Sackler Faculty of Medicine, Tel Aviv University, Israel and <sup>3</sup>Department of Physiology, Medical College of Ohio, Toledo, OH, USA

<sup>4</sup>To whom correspondence should be addressed at: Department of Obstetrics and Gynecology, Rabin Medical Center, Beilinson Campus, Petah Tiqva 49100, Israel. E-mail: yigalgat@yahoo.com

**BACKGROUND:** Varicocele is a bilateral vascular disease, involving a network of collaterals and small, retroperitoneal bypasses. The right and the left testicular venous drainage systems are complex and not identical to each other. It was considered a predominantly unilateral (left-sided) disease. Its pathophysiology has not been clearly delineated and the treatments offered do not seem to be effective. The medical literature is replete with articles demonstrating inconsistent and even contradictory results which have led clinicians to dissociate varicocele from male infertility. Since male fertility is preserved with only one healthy testis, male infertility perforce represents bilateral testicular dysfunction. This poses an enigma to clinicians: How can left-sided varicocele causes bilateral testicular dysfunction? **METHODS:** We investigated the internal spermatic veins by venography to understand testicular damage due to varicocele. A total of 740 venographies of the internal spermatic veins (ISVs) were performed, with sclerotherapy of the ISV as treatment for varicocele. Epon-embedded testicular tissue sections were used to identify blood stagnation in the testis. **RESULTS:** Varicocele is predominantly a bilateral disease in 84% of cases, associated with collaterals and retroperitoneal venous bypasses in 70% in the left side and 75% in the right side. Histopathology demonstrate stagnation in the testicular microcirculation and hypoxic-ischaemic degenerative changes in all cells' types in the sperms' production site. **CONCLUSION:** Based on our findings (i) varicocele is a bilateral disease; (ii) the disease is expressed earlier in the left side and is more intense because the blood column is longer in the left side than the right; (iii) partial treatment to the left side only and ignoring bypasses is not adequate to correct the problem; (iv) hypoxia leading to ischaemic damage to both testes is the effect of varicocele due to hydrostatic pressures in the impaired venous drainage system, which exceeds the pressures in the testicular arterial microcirculation due to blood columns produced in the disease; (v) hydrostatic pressure does not depend on vein diameter but on blood column height, only; and (vi) thermography alone or combined with ultrasonography with special attention to the bilaterality of the disease are the best non-invasive tools for its detection.

*Key words:* hypoxia/male fertility/varicocele

## Introduction

A major cause of male infertility is varicocele, which is almost always treatable. Based on the recent findings by our team and other investigators, we have concluded that varicocele is a bilateral vascular disease. (Matthews *et al.*, 1998; Gat *et al.*, 2004a).

Since an impaired venous drainage system of the testis is the cause of this condition, it should not affect only the left side. However due to the higher hydrostatic pressure in the left internal spermatic veins (ISVs), the severity of the disease is greater on the left side. The destruction of one-way valves produces blood columns with a length of 40 cm on the left side and of 35 cm on the right side. High hydrostatic pressure is exerted on the pampiniform plexus. When venous pressures

exceed the arteriolar pressures in the testicular microcirculatory system, the same hypoxic effect on the testicular tissue occurs on both sides. This adverse effect is due to hydrostatic pressure and lack of proper drainage. The blood becomes stagnated and, as a consequence, oxygenated arteriolar blood cannot flow normally into the testis (Chakraborty *et al.*, 1985; Gat *et al.*, 2003). The intra-abdominal portion of the testicular venous drainage is highly complex, with a remarkable network of small (0.1–0.3 mm diameter) retroperitoneal veins (Kunnen and Comhaire, 1992; Gat *et al.*, 2004c), which serve as bypasses. This venous network is associated with varicocele disease, which is non-palpable and cannot be diagnosed by Valsalva's manoeuvre, especially on the right side. Therefore, bilateral varicocele remains undiagnosed on physical

examination by palpation (Gat *et al.*, 2004c). It must be noted, however, that both palpable and non-palpable veins have the same detrimental effects on the testis, leading to oligotera-toasthenospermia (OTA) with different degrees of severity. Male infertility is preserved with only one healthy testis. Therefore OTA (mild, moderate, severe, extremely severe or azoospermia) perforce represent bilateral testicular dysfunction (Gat *et al.*, 2005). Adequate treatment of the testicular venous drainage system by blocking the hydrostatic pressure may reverse bilateral testicular dysfunction and improve spermatogenesis and testosterone production. Treatment can be carried out effectively by percutaneous sclerotherapy or by microsurgery. Application of this technique to patients by our group and others showed about 80% improvement in spermatogenesis with an ~40% pregnancy rate (Matthews *et al.*, 1998; Kim *et al.*, 1999; Pasqualloto *et al.*, 2003; Gat *et al.*, 2005) and an increase in testosterone production (Comhaire and Vermeulen, 1975; Su *et al.*, 1995; Gat *et al.*, 2004b).

## Materials and methods

We have reviewed the records of venographies of 740 consecutive infertile men whose infertility was of at least 12 months duration who were evaluated for male infertility. One hundred and twelve of them were pre-diagnosed with varicocele. Patient ages ranged from 20 to 52 years. All participants underwent a complete history, physical examination, hormone profile, and genetic testing if needed. Patients with cryptorchidism or testicular trauma, and patients after surgery of the urogenital tract or genetic problems were excluded.

Patients were examined in a warm room after standing for 5 min. The volume, position and consistency of the testes and epididymis were checked, and each spermatic cord was palpated in the standing position and during the Valsalva manoeuvre. Findings were graded according to the system of Dubin and Amelar as follows: grade I = varicocele palpable only during Valsalva's manoeuvre; grade II = varicocele palpable in the standing position; grade III = varicocele detectable by visual scrutiny alone (Dubin and Amelar, 1971). All patients were examined by a senior highly experienced andrologist. All patients underwent contact thermography using a flexible liquid crystal thermstrip (FertiPro, Breemen, Belgium). Percutaneous sclerotherapy of the ISVs was performed followed by bilateral venography by the Gat–Gornish technique (Gat *et al.*, 2004a), enabling detection of the damaged right testicular venous drainage system including associated bypasses and collaterals, a modified technique first described by Kunnen (Kunnen and Comhaire, 1992).

Pathophysiological studies were carried out by using epon-embedded testicular tissue samples from patients with varicocele. Tissue samples were obtained from our collection with the approval of the Internal Review Board (IRB) of the Medical College of Ohio. Tissue sections were examined under a Nikon Optiphot light microscope and micrographed at variable magnifications.

**Table I.** Incidence of bilateral, left sided and right sided varicocele

	No. of cases	Incidence (%)
Total no. of venographies	740	
Bilateral varicocele	620	84
Left sided varicocele	104	14
Right sided varicocele	16	2

**Table II.** Incidence of bypasses

	No. of cases	Incidence (%)
Total no. of venographies	740	
Total cases of bypasses	606	82
Left bypasses	518	70
Right bypasses	555	75

**Table III.** Incidence of subclinical varicocele

	No. of cases	Incidence (%)
Total no. of venographies	740	
Left subclinical varicocele (non-palpable)	103	14
Right subclinical varicocele (non-palpable)	681	92

## Results

Bilateral varicocele was detected by venography in 620 of 740 patients (84%). Left sided varicocele was found in 104 cases (14%), and right sided varicocele was diagnosed in 16 cases (2%) (Table I).

Bypasses were demonstrated by venography in 606 cases (82%). Bypasses were demonstrated on the left side in 518 cases (70%), and on the right side in 555 cases (75%). All these bypasses were without one-way valves and demonstrated back-flow as seen by venography (Table II).

Subclinical varicoceles which were not detected by palpation were diagnosed by thermography confirmed by venography in 103 on the left side (14%), and in 681 cases on the right side (92%) (Table III).

Severe stagnation of blood was observed in small arterioles, venules and capillaries (Figure 1a and b) of the testis, leading to is spermatogenic damage.

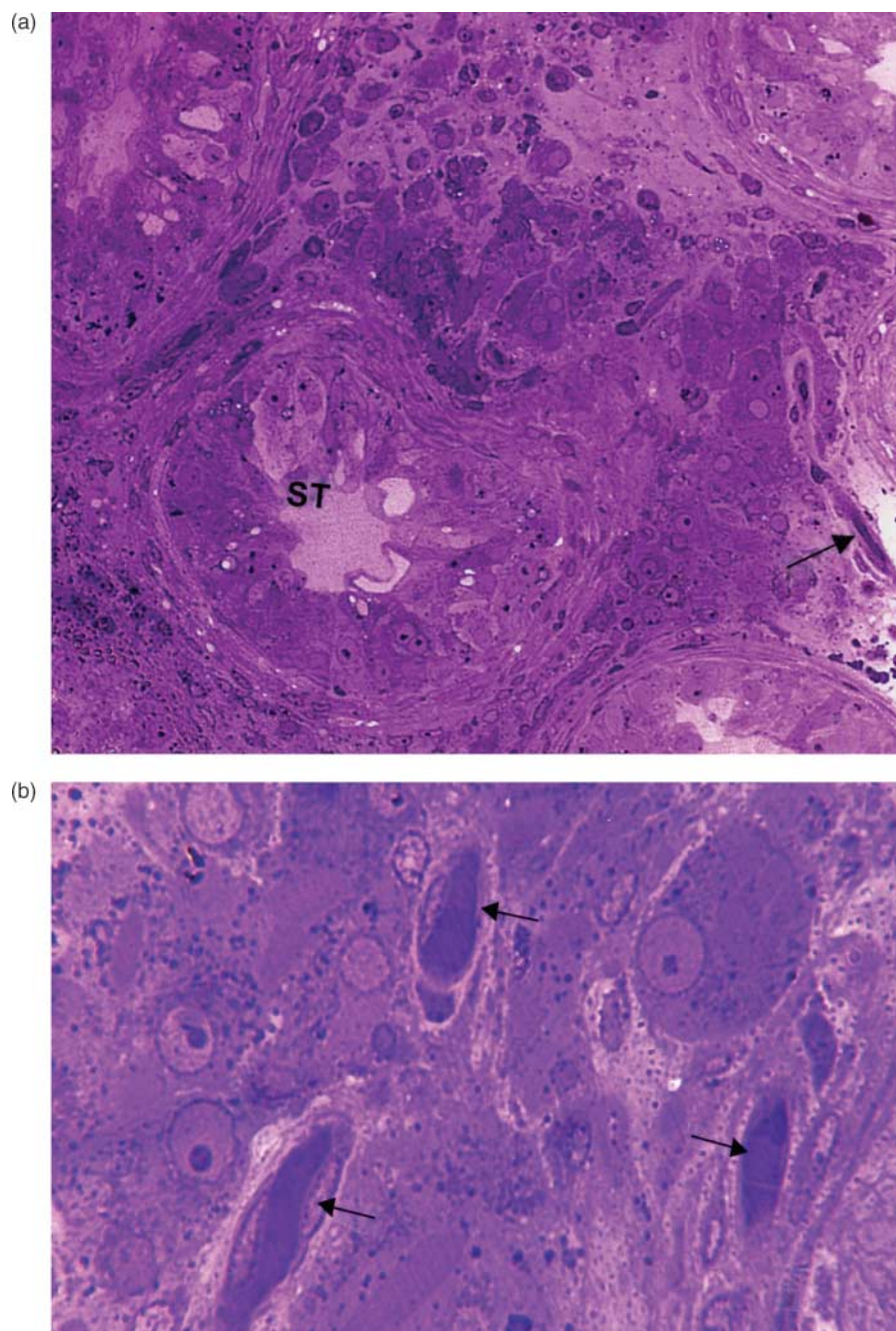
## Discussion

Back-flow in the testicular venous drainage system, as seen in venography, is the ultimate physical proof that one-way valves are destroyed. As a result of the incompetence of the valves, additional extreme high hydrostatic pressure (some 6–7 times above the normal physiological condition, parallel to the 6–8 one-way valves which were destroyed) is exerted on the pampiniform plexus. This hydrostatic pressure (which can be measured by the height of the blood column) causes high pressure on the venules in the microcirculation of the testicular tissue. Physical examination is used as the standard diagnostic method for clinical varicocele. However, it is subjective and may be associated with significant interphysician variability. Therefore, using the fingers has a limited capacity to detect blood flow changes especially in subclinical varicocele.

The hydrostatic pressures can be estimated according to Equation 1 which determines the pressure as a function of the fluid column height (Streeter, 1971, p. 31):

$$P = \phi \times g \times h \quad (1)$$

Where: P = hydrostatic pressure,  $\phi$  = density, g = gravity and h = vertical height of the fluid column. Each 1.0 cm of



**Figure 1.** (a) Testicular tissue of a man with varicocele, showing stagnation of blood in the microcirculatory system (arrows) and the ischaemic degenerative changes to the seminiferous tubules (ST)  $\times 200$ . Note the degeneration of germ cells indicated by numerous vacuoles in the seminiferous tubules (ST). (b) Testicular tissue with the same condition as in (a), showing the stagnation of blood in the venules. Microcirculatory vessels are clogged with blood (arrows), at a higher magnification (arrows)  $\times 800$ .

blood column contributes 0.77 mmHg. to the total pressure (Ganong, 1999, pp. 550–570).

According to Equation 1 (a derivative of the laws developed by Newton and Pascal), the elevated hydrostatic pressure in the system does not depend on the vessel diameter but rather on the height of the column of fluid (blood) and its density. Therefore, small and non-palpable veins have the same hypoxic effect on sperm production as do enlarged, palpable veins.

The right and the left testicular venous drainage systems are complex and do not have identical fluid dynamics. The venous system lends itself to analysis using the well-known principles of physics, including flow dynamics and strength of materials. The venographies show that ISV reflux is predominantly a bilateral phenomenon in 84% of cases and is associated with collaterals and retroperitoneal venous bypasses in 70% on the left side and 75% on the right side.

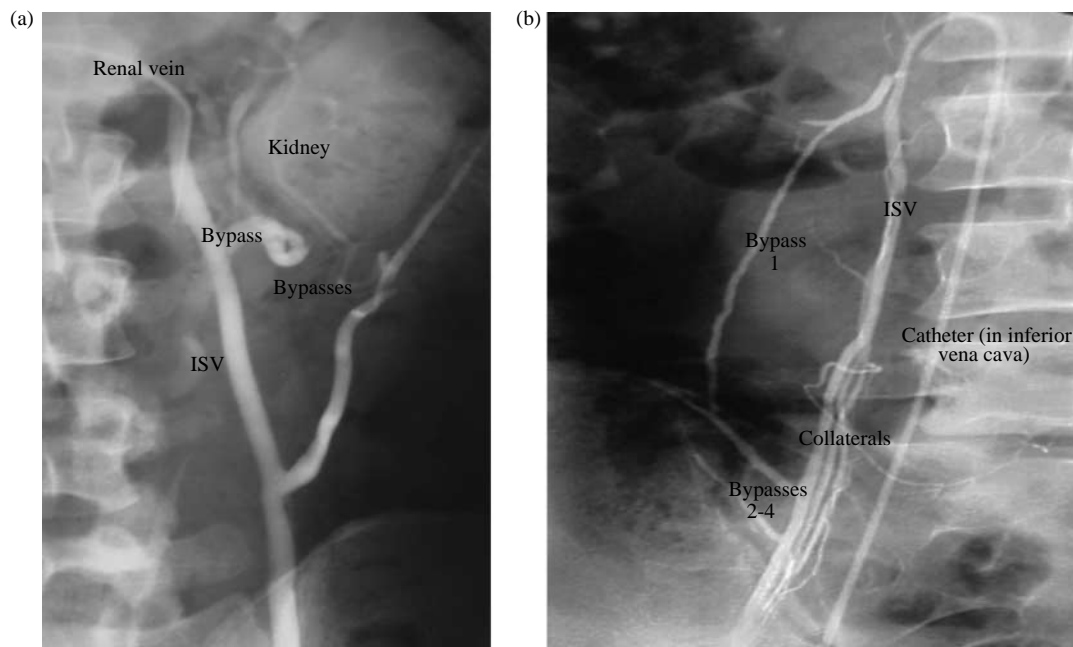


According to our findings, the pathophysiological mechanism involved in varicocele is the hydrostatic pressure (31mmHg=40cm blood column) of the venous blood column transmitted caudally to the pampiniform plexus. Blood-Flow is possible only in the direction of negative pressure gradient, so when that pressure exceeds the arteriolar pressure, (18-20mmHg) (Ganong 1999) there is relative hypoxia of the testicular tissues. The hypoxic–ischaemic state affects seminiferous tubules, Sertoli cells, germ cells and later Leydig cells (Figure 1a and b). It results in impaired sperm quality and reduction of the quantity, eventually leading to mild, moderate, severe and extremely severe OTA and azoospermia (Matthews *et al.*, 1998; Gat *et al.*, 2004a). Complete treatment of the disease, namely occlusion of bilateral ISVs with the entire network of the associated venous bypasses, results in significant improvement in sperm production and pregnancy achievement even in azoospermic men (Matthews *et al.*, 1998; Pasqualloto *et al.*, 2003; Gat *et al.*, 2005); this improvement could be achieved since the treatment was performed by embolization or by microsurgery. Percutaneous sclerotherapy (or embolization), using interventional radiological techniques or microsurgery, is effective in eliminating the pathological hydrostatic pressure allowed by incompetent, destroyed, one-way valves in the ISV and/or the accompanying fine (and sometimes nearly microscopic) network of retroperitoneal venous bypasses. Both techniques enable

control and occlusion of the entire network of venous bypasses associated with the malfunctioning ISV on both sides that produce elevated hydrostatic pressure (Figure 2a and b) regardless of the diameter of the veins (Equation 1). Elimination of the pathological hydrostatic pressure by these treatments will result in restoring normal arterial oxygenated blood flow (Comhaire *et al.*, 1983) and normal supply of nutrient materials to the seminiferous tubules—the sperms' production site. Of course, by definition, from a biological point of view, this process will improve the hypoxic situation. If the hypoxia is too long standing it will cause capillary fibrosis and irreversible change to spermatogenesis.

A recent study demonstrated that for infertile couples undergoing intrauterine insemination in whom the female partner was normal and the male had varicocele, pregnancy and live birth rates were significantly higher if the man underwent varicocele treatment (Daitch *et al.*, 2001)

Recent editorial comments by Nagler (2004) on our previous study, which describes why the detection of the right side was missed (Gat *et al.*, 2004c), are in conflict with our anatomic and physical findings. Three major concerns of Nagler's comments need to be addressed regarding varicocele: first, does varicocele relate to male infertility? Secondly, is subclinical varicocele relevant to male infertility, which requires treatment? Thirdly, is ultrasonography better, because venography is subject to technical variations?



**Figure 2.** (a) Left side venography of a patient with bilateral varicocele demonstrating the dilatation of the left internal spermatic vein (after the destruction of one-way valves), associated with a network of venous bypasses going around the kidney and towards the internal adrenal vein with diameters ranging from 0.3 to 3 mm. This is a classic case where left high ligation only would miss the treatment of the bypasses and 'recurrent varicocele' would be diagnosed after a few months. If sperm production improves, it will be temporary only. (b) The same patient. Venography on the right side demonstrating the enlarged ISV associated with a complex network of venous bypasses and retroperitoneal collaterals, going towards the renal vein and the kidney with diameters ranging from 0.1 to 1.0 mm. This is a classic case where the right side varicocele was missed by physical examination and, without venography combined with embolization (or microsurgery), the treatment would have been missed. Note the long vertical blood column of 35 cm which exerts hydrostatic pressure of 27 mmHg ( $P = \phi \times g \times h$ ) on the testicular microcirculation in the pampiniform plexus, which exceed the hydrostatic pressure in the arterioles, leading to blood stagnation and hypoxia in the seminiferous tubules.

These concerns have serious implications in the treatment of infertile males and demand proper explanation.

### ***Does varicocele relate to male infertility?***

The concept that varicocele does not relate to male infertility is supported by the comprehensive meta-analysis of seven prospective randomized studies conducted in the last two decades, which concluded that 'varicocele repair does not seem to be an effective treatment for male subfertility'. (Evers and Collins, 2003). This concept is supported further by repeated comprehensive analysis in *Cochrane Database Systematic Reviews* 2004 (Evers and Collins, 2004) where the reviewers concluded from the results of eight controlled prospective randomized studies 'indicating no benefit of varicocele treatment over expectant management in subfertile couples in whom varicocele in the man is the only abnormal finding'.

These results contradict our findings, but it is not surprising since, according to usual practice, the vast majority of patients in these studies were treated partially, on the left side only.

Until now, the bilaterality of varicocele has gone largely unrecognized and the network of bypasses and collaterals are not seen at surgery by high ligation; therefore, they were either not treated, or partially treated.

We have estimated that only ~20% of the patients in these studies on which those conclusions are based were treated adequately. These include the patients who did not have right varicocele; their varicocele was not associated with collaterals and venous bypasses; or they did not have significant inter-testicular venous connections. The remaining 80% were treated partially with either no improvement or transient improvement in fertility. When partial treatment (left high ligation-occlusion of the main ISV) alone is performed, the remaining collateral veins will enlarge to accept a greater volume of blood, in order to maintain (a simple law of flow mechanics) hydrodynamic equilibrium in the drainage system consisting of elastic vessels. That will eventually result in what we call 'survived', or 'secondary' varicocele (mistakenly called 'recurrent varicocele' in the medical literature).

Our conclusion is that the proper interpretation of these two comprehensive meta-analyses should state that inadequate treatment techniques carried out in these studies for varicocele repair indeed do not improve fertility in affected males.

### ***Is subclinical varicocele relevant to male infertility, which requires treatment?***

Varicocele is the main cause of male infertility. However, poor results of inadequate treatment have led those working in the field to ignore the pathophysiological connection between the cause of varicocele (hydrostatic pressure and hypoxia) and its ultimate effect on sperm production.

As we have stated above, the small veins contribute significantly to the problem of high hydrostatic pressure and hypoxia in the microcirculatory system of the testes, which make its proper treatment more complex than the solution provided by simple traditional surgical techniques.

The hydrostatic pressure, created by the destruction of the one-way valves in the testicular venous drainage system, depends primarily on the height of the vessels and the density of the blood. The pressure transmitted through the ISV does not depend on the diameter, geometry or flow rate of the veins (Equation 1). Small veins which may not be palpable by the fingers of the best clinician can be as effective in transmitting these elevated pressures to the pampiniform plexus. Regardless of whether the vessels are palpable or not, the very existence of vertical blood vessels without competent valves that produce 40 cm of blood column causes high hydrostatic pressure in the venous system which exceeds the pressure in the arteriole system. It leads to stagnation of blood flow in the testicular microcirculatory system and hypoxia in the testicular tissues (Chakraborty *et al.*, 1985). Hypoxia will cause tissue damage and progressive deterioration of sperm production, resulting in infertility. (Gorelick and Goldstein, 1993; Matthews *et al.*, 1998; Cozzolino and Lipshultz, 2001; Gat *et al.*, 2005) regardless of the diameter of the veins.

### ***Is ultrasonography better because venography is subject to technical variations?***

Venography shows, in real time, the direction of blood flow in the spermatic veins. Using manual injections with a tilt table, one can demonstrate the residual traces of incompetent or destroyed valves, partially or intermittently competent valves, and the collaterals and venous bypasses associated with the varicocele. The ideal treatment modality is to allow the clinician to obtain the most detailed anatomic, physiological and pathophysiological information possible before and while performing interventional treatment. The imaging achieved with ultrasonography may provide certain additional dimensions of information about blood flow in the testis, but cannot address the anatomy of the retroperitoneal ISV system. More important to our discussion of right sided reflux is the fact that because back-flow cannot be produced by the Valsalva manoeuvre, ultrasonography cannot detect reflux easily on the right side. Imaging of the colour flow Doppler is based on minimal resolution threshold of flow. It is difficult to detect small amounts of reflux in the right side, even for an experienced ultrasonographer.

A simple, sensitive and easy to use detector for screening right varicocele is contact thermography. Contact thermography is based on conductivity of the heat transferred from the abdominal level of the right spermatic vein downstream to the level of the pampiniform plexus where the patient is being examined. It does not depend on blood flow but on the conductivity of the heat only. Since it is impossible to produce back-flow in the right side (reflux) by Valsalva's manoeuvre (as seen in venography), higher sensitivity and accuracy are achieved by thermography. In our experience, contact thermography is the best single tool for screening and, combined with ultrasonography, yields the highest sensitivity and accuracy in the diagnosis of bilateral varicocele (Gat *et al.*, 2004a,c).

## Conclusion

The right and the left testicular venous drainage systems are complex and not identical on both sides. Varicocele is a bilateral disease. A network of commonly found collaterals and small, retroperitoneal bypasses are associated with the disease. Hydrostatic pressure of a blood column which causes hypoxia does not depend on its diameter but on its height only. Therefore, a small and non-palpable vein with reflux as seen with venography has the same adverse effect on male infertility as do large palpable veins. Right varicocele cannot be detected by palpation; therefore, using thermography alone or combined with ultrasonography, with special attention paid to the bilaterality of the disease, are the best screening tools for detecting the disease. Sclerotherapy performed as an interventional radiological procedure, or microsurgery, are effective treatments in blocking the high hydrostatic pressure in the entire network of the impaired testicular venous drainage system, which causes fertile men to become infertile.

## References

- Chakraborty J, Sinha Hikim AP and Jhunjhunwala JS (1985) Stagnation of blood in the microcirculatory vessels in the testes of man with varicocele. *J Androl* 6,117–126.
- Comhaire F and Vermeulen A (1975) Plasma testosterone in patients with varicocele and sexual inadequacy. *J Clin Endocrinol Metab* 40,824–829.
- Comhaire F, Simons M, Kunnen M and Vermeulen L (1983) Testicular arterial perfusion in varicocele: the role of rapid sequence scintigraphy with technetium in varicocele evaluation. *J Urol* 130,923–926.
- Cozzolino DJ and Lipshultz LI (2001) Varicocele as a progressive lesion: positive effect of varicocele repair. *Hum Reprod Update* 7,55–58.
- Daitch JA, Bedaiwy MA, Pasqualotto EB, Hendin BN, Hallak J, Falcone T, Thomas AJ Jr, Nelson DR and Agarwal A (2001) Varicocelectomy improves intrauterine insemination success rates in men with varicocele. *J Urol* 165,1510–1513.
- Dubin L and Amelar RD (1971) Etiologic factors in 1294 consecutive cases of male infertility. *Fertil Steril* 22,469–474.
- Evers J and Collins A (2003) Assessment of efficacy of varicocele repair for male subfertility: a systematic review. *Lancet* 361,1849–1852.
- Evers JL and Collins JA (2004) Surgery or embolization for varicocele in subfertile men. *Cochrane Database Syst Rev* 3,CD000479.
- Ganong WF (1999) *Medical Physiology*. 19th edn. Lange Medical Books/McGraw-Hill, New York, pp. 550–567.
- Gat Y, Zukerman Z, Bachar GN, Feldberg D, Belenky A and Gornish M (2003) Adolescent varicocele: is it a unilateral disease? *Urology* 62, Discussion 742–747.
- Gat Y, Bachar GN, Zukerman Z and Gornish M (2004a) Varicocele: a bilateral disease. *Fertil Steril* 81,424–429.
- Gat Y, Gornish M, Belenky A and Bachar GN (2004b) Elevation of serum testosterone and free testosterone after embolization of the internal spermatic vein for the treatment of varicocele in infertile men. *Hum Reprod* 19,2303–2306. Editorial comment in *J. Urol* June 173 (6) 2079.
- Gat Y, Bachar G, Zukerman Z, Belenky A and Gornish M (2004c) Physical examination may miss the diagnosis of bilateral varicocele: a comparative study of four diagnostic modalities. *J Urol* 172,1414–1417. Editorial 1239–1240 and Discussion in *J. Urol* June 173 (6), 2208–2209.
- Gat Y, Bachar GN, Everaert K, Levinger U and Gornish M (2005) Induction of spermatogenesis in azoospermic men after internal spermatic veins embolization for the treatment of varicocele. *Hum Reprod* 20,1013–1017.
- Gorelick JJ and Goldstein M (1993) Loss of infertility in men with varicocele. *Fertil Steril* 59,613–616.
- Kim ED, Leibman BB, Grinblat DM et al. (1999) Varicocele repair improves semen parameters in azoospermic men with spermatogenic failure. *J Urol* 162,737–740.
- Kunnen M and Comhaire F (1992) Nonsurgical cure of the varicocele by transcatheter embolization of the internal spermatic veins with tissue adhesive (histoacryl transparent). In Castaneda-Zuniga WR and Tadavarthy SM (eds) *Interventional Radiology*, 2nd edn. Williams & Wilkinson, Baltimore, pp. 73–100, part 2.
- Matthews GJ, Matthews ED and Goldstein M (1998) Induction of spermatogenesis and achievement of pregnancy after microsurgical varicocelectomy in men with azoospermia and severe oligoasthenospermia. *Fertil Steril* 70,71–75.
- Nagler HM (2004) Varicocele. Where, why and, if so, how? *J Urol* 172,1239–1240.
- Pasqualotto FF, Lucon AM, Hallak J et al. (2003) Induction of spermatogenesis in azoospermic men after varicocele repair. *Hum Reprod* 18,108–112.
- Streeter VL (1971) *Fluid Mechanics*, 5th edn. McGraw-Hill, New York.
- Su LM, Goldstein M and Schlegel PN (1995) The effect of varicocelectomy on serum testosterone levels in infertile men with varicocele. *J Urol* 154,1752–1755.

*Submitted on February 8, 2004; resubmitted on April 14, 2005; accepted on April 22, 2005*